

## A Rare Diagnostic Evidence Report of Early Management of Amlodipine Induced Gingival Enlargement with Stress As Confounding Element.

Lavanya Pragada<sup>1</sup>, Kanchan Arya<sup>2</sup>, Triveni M.G<sup>3</sup> Jayasheela M<sup>4</sup>, Mehta D.S<sup>5</sup>

<sup>1</sup>Post Graduate Student, Department Of Periodontics, Bapuji Dental College And Hospital, Davangere

<sup>2</sup>Post Graduate Student, Department Of Periodontics, Bapuji Dental College And Hospital, Davangere

<sup>3</sup>Professor, Department Of Periodontics, Bapuji Dental College And Hospital, Davangere

<sup>4</sup>Department Of Periodontics, Bapuji Dental College And Hospital, Davangere

<sup>5</sup>Professor And Head Of The Department, Department Of Periodontics, Bapuji Dental College And Hospital, Davangere

---

**Abstract:** Gingival overgrowth arises chiefly as a consequence of certain anti-seizure, immunosuppressive, or antihypertensive medications. Excessive gingival tissues hampers oral function, compromises oral hygiene and produces a considerable aesthetic disfigurement. Owing to an ambiguous pathogenesis several factors like age, drug doses, genetic factors, and plaque induced inflammation, etc. proposed jeopardize the dental treatment. The development of novel preventive and therapeutic modalities to treat gingival overgrowth entails a systematic approach. The management is largely targeted on accurately diagnosing, drug substitution and effective exclusion of local inflammatory elements. When these measures fail to resolve the enlargement, surgical intervention is recommended. The objective of the present case report is to present the clinical features, factors and treatment of combined inflammatory gingival enlargement which disturbed the aesthetics and masticatory function of the patient.

**Keywords:** Drug induced gingival enlargement, calcium channel blockers, Amlodipine, stress, Perceived stress scale.

---

### I. Introduction

“Health is wealth”, as alluded by our ancestors accentuating the necessity of a healthy living for greater good of the individual. In today’s generation science has discovered beyond belief ways to curb virtually every disease known to mankind with the aid of ever rising field of apothecary. The incredible advancements in this field steered to the development of numerous medicines to treat diverse diseases from acute to chronic. Nevertheless, as justly believed every coin has two sides, majority of medicinal principal’s leads to unavoidable side-effects. One of such inevitable prominent effect that gained importance over the years is gingival enlargement owing to drugs which yields functional and aesthetic disfigurement and confronts normal oral hygiene. An elaborate exploration of literature reveals that most common culprits from periodontal point of view are selected anti-convulsants, calcium channel blockers and immunosuppressants<sup>[1]</sup>.

Calcium channel blockers commonly abbreviated as CCB’s are a set of drugs devouring extensive usage in the treatment of cardiovascular illnesses such as angina pectoris, hypertension and cardiac arrhythmias<sup>[2]</sup>. The reported rate of occurrence of gingival enlargement with CCBs is estimated to be 10%. The present article emphasizes upon successful early management of drug induced gingival enlargement with stress as a factor utilising surgical approach.<sup>[3]</sup>

### II. Case Report

A 22 year old male patient reported with the chief grievance of swollen gums in lower front teeth since six months and bleeding while brushing.(Figure1) On eliciting his medical status the patient revealed that he was a hypertensive since two and a half years and was prescribed Amlodipine (5mg once daily) with no other significant findings. Patient’s family history in regards to hypertension was insignificant. Nonetheless; he furnished a personal history of not having a secured job and means of living which became a reason for his concern and distress. A 10-item perceived stress scale devised by Sheldon Cohen<sup>[1]</sup> was given to the patient at baseline and after 6 months. The values recorded were 35 at baseline which declined to 25 after 6 months thereby establishing a decrease in the level of anxiety over a period of time brought about by psychological counselling.

Intra-oral examination displayed bleeding on probing. Generalised gingival inflammation was evident along with enlargement of the marginal and interdental papilla extending from 33 to 43. Further periodontal and radiological examination revealed generalised deep periodontal pockets with inconsistent bone loss. Routine

complete blood investigations together with triglyceride status were within the normal range. Henceforth, a final diagnosis of combined gingival enlargement -Inflammatory and drug induced was established.

After obtaining the physician’s opinion, Telmistantan 40 mg once daily substituted the previously prescribed amlodipine (Angiotensin II receptor antagonist- blocks activation of peroxisome proliferator-activated receptor gamma). It widens the blood vessels by hindering the activity of Angiotensin and causing diminution of the blood pressure.<sup>[4]</sup>

**Treatment:**

The treatment procedure was explicated to the patient. Scaling and root planning was accomplished and the patient was instructed to apply topical metronidazole (10%) gel along with rinsing with chlorhexidine mouthwash twice daily till the completion of surgical phase. Re-evaluation of patient’s oral hygiene status ascertained satisfactory outcomes and hence a plan for full mouth periodontal flap surgery was devised. (Figure 2) A referral to psychiatrist was made to ascertain that he was counselled for the adverse effects of stress and effectives ways of management.

After inducing adequate anaesthesia with 2% xylocaine HCl, modified flap operation was performed by raising a full thickness flap. Subsequently through debridement of the root surface was completed and osseous recontouring was performed when required. Platelet rich fibrin(PRF) was placed in the areas of accentuated bone loss and the surgical site was sutured. Post operatively, antibiotics (amoxicilline-500 mg) thrice daily for 5 days and analgesics (paracetamol 500 mg and diclofenac sodium -50 mg) were prescribed. Patient was placed under periodically planned follow-up along with reinforcement of oral hygiene guidelines. Six months post-operative follow up exhibited satisfactory oral hygiene maintenance with no recurrence of gingival enlargement. (Figure 3) Patient was then kept under regular recall and maintenance.

**III. Discussion**

Periodontium formulates the tooth supporting apparatus which is pivotal for the tooth to remain in position. As deliberated by Schenkein et al, host inflammatory response not only preserves the periodontium, it equally determines the extent of destruction by periodontal diseases. Seymour et al in his paper also pointed out to the innumerable interactions of systemic medication and periodontium.<sup>[5]</sup>

Amlodipine, second generation dihydropyridine calcium antagonist acts on L-type calcium channels inhibiting the influx of calcium ions and impairing the actin myosin complex bringing about muscle contraction. The net consequence of this is lowering of hypertensive status.<sup>[6]</sup> A Literature review emphasized that amlodipine is a safe drug with adverse effect limited to dizziness.<sup>[7]</sup>

Diversifying theories have been put forth to elucidate the mechanism of gingival over growth for instance formation of inactive collagenase, sensitization of fibroblasts and overgrowth as a response to bacterial plaque. It has been advocated that as CCB’s precludes the entry of calcium affecting the turnover rate of collagen affecting the extra-cellular matrix degradation inducing the over growth. The consequence being deranged plaque control paving a way for inflammation and further progression of enlargement. Scientific literature remarked that enlargement associated with CCBs is routinely evident on the facial surfaces of anterior teeth.<sup>[2]</sup> In congruent to that the present case likewise displayed the enlargement on facial surfaces of lower anterior teeth.

Most likely stress represented as a confounding factor in the above stated case (established by perceived stress scale -Figure 1.)<sup>[8]</sup> The patient was strained due to his unstable job profile that may have triggered the rise in blood pressure levels further worsening the periodontal status. Stress diverts patient’s attentiveness making them neglect their overall health and oral hygiene plunging them to develop periodontitis. However, existence of hypertension and its consequent enlargement at such an early age is quite conspicuous. Pre-existing periodontitis by virtue of etiological deposits in conjunction with stress may have precipitated to elevated production of immunosuppressive glucocorticoids which additionally degraded the immune response. (Figure 2)<sup>[9]</sup>

**Figure 1: Perceived stress scale**

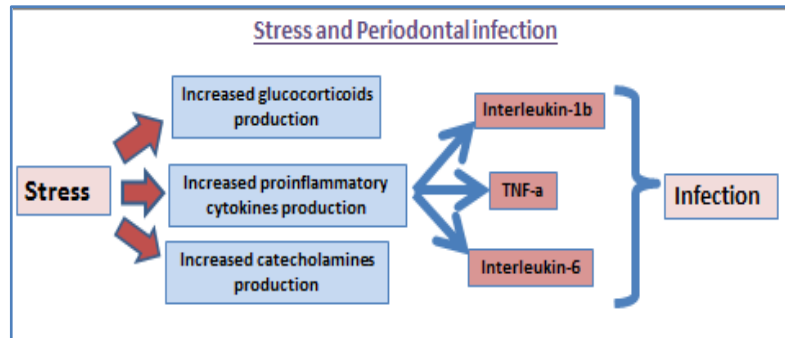
**Perceived Stress Scale**

The questions in this scale ask you about your feelings and thoughts during the last month. In each case, you will be asked to indicate by circling how often you felt or thought a certain way.

Name \_\_\_\_\_ Date \_\_\_\_\_  
 Age \_\_\_\_\_ Gender (Circle): M F Other \_\_\_\_\_

0 – Never    1 – Almost Never    2 – Sometimes    3 – Fairly Often    4 – Very Often

1. In the last month, how often have you been upset because of something that happened unexpectedly? .....	0	1	2	3	4
2. In the last month, how often have you felt that you were unable to control the important things in your life? .....	0	1	2	3	4
3. In the last month, how often have you felt nervous and "stressed"? .....	0	1	2	3	4
4. In the last month, how often have you felt confident about your ability to handle your personal problems? .....	0	1	2	3	4
5. In the last month, how often have you felt that things were going your way? .....	0	1	2	3	4
6. In the last month, how often have you found that you could not cope with all the things that you had to do? .....	0	1	2	3	4
7. In the last month, how often have you been able to control irritations in your life? .....	0	1	2	3	4
8. In the last month, how often have you felt that you were on top of things? .....	0	1	2	3	4
9. In the last month, how often have you been angered because of things that were outside of your control? .....	0	1	2	3	4
10. In the last month, how often have you felt difficulties were piling up so high that you could not overcome them? .....	0	1	2	3	4



**Figure 2:** Role of stress in periodontal infection

Since there is a near equal escalation of hypertension in the contemporary world, it can be claimed that number of individuals affected with gingival overgrowth will also accelerate in future as CCBs form the main stay drugs in treatment of hypertension. Comprehensive management involves lessening the degree of enlargement so that patient does not have difficulty in speech, mastication and oral hygiene maintenance. In the current case, patient's demand pertaining to aesthetics and mastication was satisfied. These treatment modalities, even though effective, do not essentially avert recurrence of the lesions.<sup>[10]</sup> In the present era of ever expanding researches, seldom do the physicians invest time on analysing the emotional mind set of the patient. However, it becomes a need of the hour to psychologically understand and motivate the patients in order to apprehend the desired treatment outcomes. Additionally, novel molecular methodologies are desirable to evidently institute the pathogenesis of gingival overgrowth and to deliver evidence for the design of future preventive and therapeutic modalities.

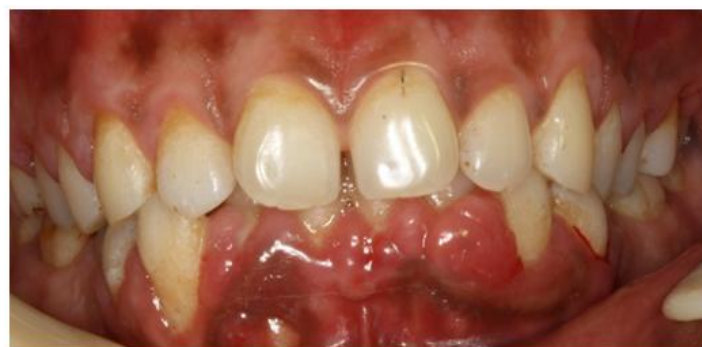Footnotes

**Source of Support:** Nil

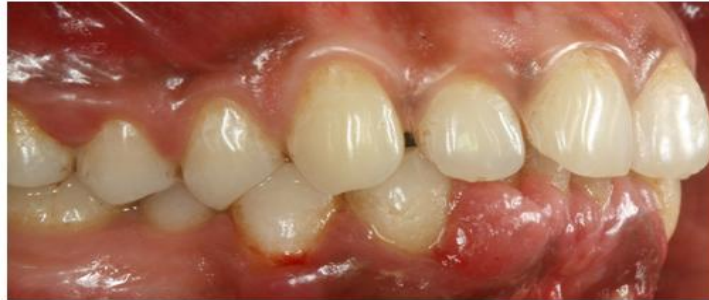**Conflict of Interest:** None declared.

### References

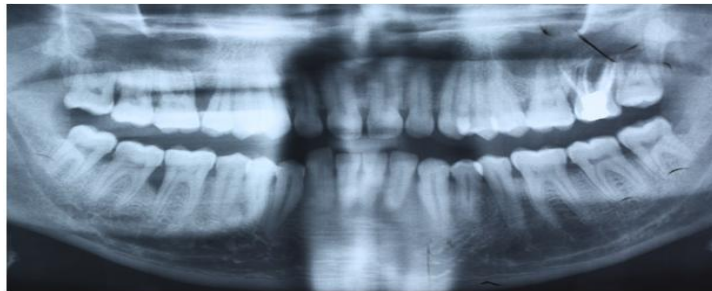
- [1]. Priyadharshini V, Belure VV, Triveni MG, Tarun Kumar AB, Mehta DS. Successful management of phenytoin and phenobarbitone induced gingival enlargement: A multimodal approach. *Contemp Clin Dent.* 2014;5:268-71.
- [2]. Hallmon WW, Rossmann JA: The role of drugs in the pathogenesis of gingival overgrowth. A collective review of current concepts. *Periodontol 2000.* 1999;21:176-96
- [3]. Seymour RA: Effect of medications on the periodontal tissues in health and disease. *Periodontol 2000.* 2006;40:120-9.
- [4]. Lorena M, Autolitano A, Natale G. Telmisartan/hydrochlorothiazide-induced hepatotoxicity. *Archives of Medical Science.* 2015;11:893-94.
- [5]. Darveau RP, Tanner A, Page RC: The microbial challenge in periodontitis. *Periodontol 2000.* 1997;14:12-32.
- [6]. Triveni MG, Rudrakshi C, Mehta DS. Amlodipine induced gingival overgrowth. *J Indian Soc Periodontol.* 2009;13:160-3.
- [7]. Sucu M, Yuce M, Davutoglu V: Amlodipine-induced massive gingival hypertrophy. *Can Fam Physician.* 2011;57:436-7.
- [8]. Cohen S. Contrasting the hassles scale and the perceived stress scale: Who's really measuring appraised stress. *American Psychologist.* 1986;41:716-18.
- [9]. Kulkarni S, O'Farrell I, Erasi M, Kochar MS: Stress and hypertension. *World Med Journal.* 1998;97:34-8.
- [10]. Dongari-Bagtzoglou A; Research, Science and Therapy Committee, American Academy of Periodontology. Drug-associated gingival enlargement. *J Periodontol.* 2004;75:1424-31.  
Cohen, S. and Williamson, G. *Perceived Stress in a Probability Sample of the United States.* Spacapan, S. and Oskamp, S. (Eds.) *The Social Psychology of Health.* Newbury Park, CA: Sage, 1988.



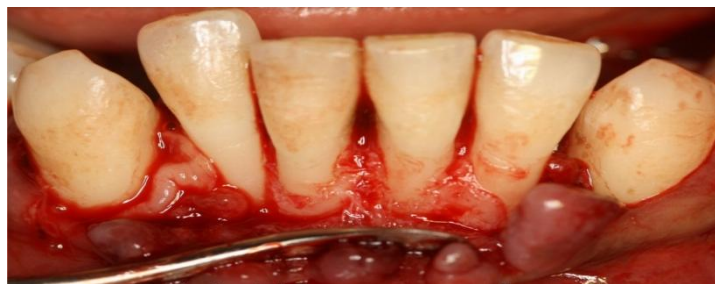Pre-Operative View (Frontal) At Baseline



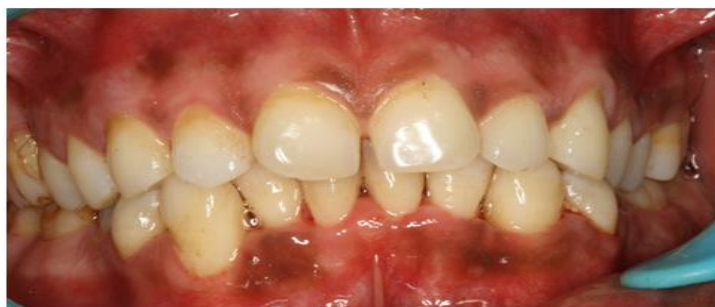Pre-Operative View (Lateral) At Baseline



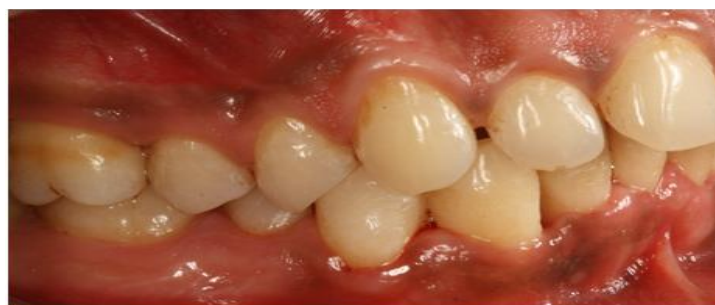Radiograph Showing Horizontal And Vertical Bone Loss



Periodontal Flap Surgery Performed



Post-Operative View (Frontal) At 6 Months



Post-Operative View (Lateral) At 6 Months